

Premolar Substitution Utilizing the

PowerScope Class II Corrector

After Extracting Transmigrated Mandibular Canines

by Andrew Hayes, DDS

Although not necessarily commonplace among the general population, canine impactions are a routine problem seen in the orthodontic office. Maxillary canines are the second most commonly impacted tooth next to the maxillary third molar and occur in approximately two percent of the population, predominantly in females.¹ Meanwhile, mandibular canines are found to impact much less frequently. In the rare circumstances when they do impact, these canines are more likely to be located on the labial side of the dental arch than are impacted maxillary canines.²

Even more uncommon than the impacted mandibular canine is the phenomenon of transmigration,³ a term coined by Ando in 1964.⁴ This describes the migration of an impacted canine across the mid-

line without the influences of a specific pathology. This phenomenon occurs almost exclusively in the mandible with an incidence of 0.48 percent.⁵ The treatment for transmigrated teeth depends on the stage of development, distance of migration, angulation of the tooth when identified and if the patient is symptomatic. Treatment options to be considered for transmigrated mandibular canines include surgical removal, surgical exposure with orthodontic alignment, and transplantation.⁶ Although transplantation has had tremendous success, which has been well documented over decades in specific areas of the world, this treatment option has not been a viable option for most practicing in the U.S. to date. It's my observation that awareness of this option is increasing due to international influence.

continued on page 26

Case study #1

This 13-year-old female presented to my office with the chief complaint of crooked teeth (Fig. 1). Her health history was unremarkable. Analysis of the case showed a Class I dental pattern, moderate maxillary and mandibular crowding, ectopic maxillary canines, which were erupting into the mouth from the buccal side, and a retained primary canine tooth. The panoramic radiograph (Fig. 2) shows a transmigrated mandibular canine with its incisal tip resting at the apex of #22 in the mandibular symphysis.

Treatment options

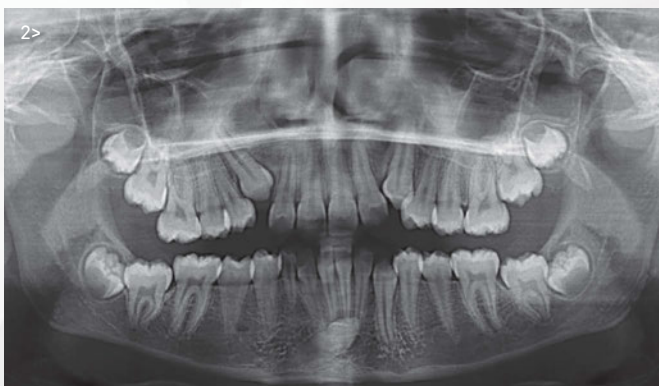
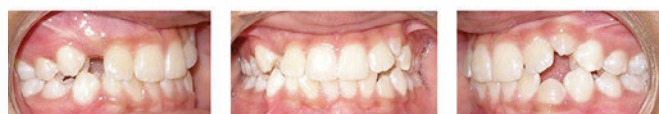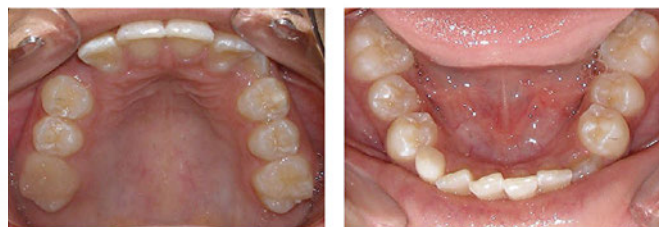1. Do nothing. Leave the impacted and retained primary teeth and monitor periodically. Bishara et al. have outlined the potential sequelae from leaving impacted canines:⁷
 - Labial or lingual malpositioning of the impacted tooth
 - Migration of the neighboring teeth and loss of arch length
 - External root resorption of the impacted tooth as well as the neighboring teeth
 - Infection related to partial eruption resulting in pain and trismus
 - Referred pain

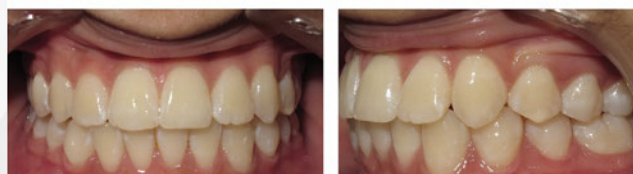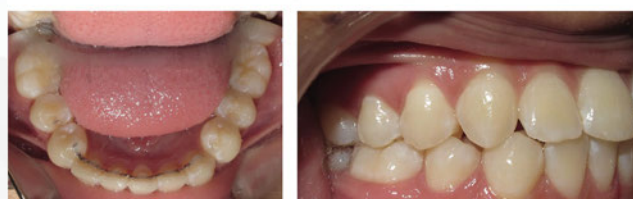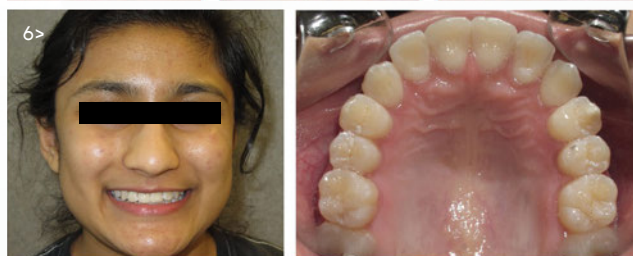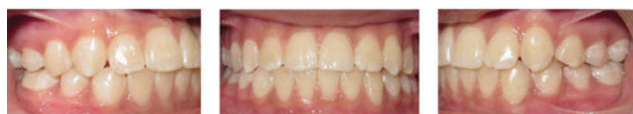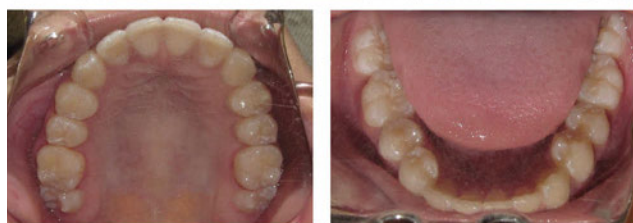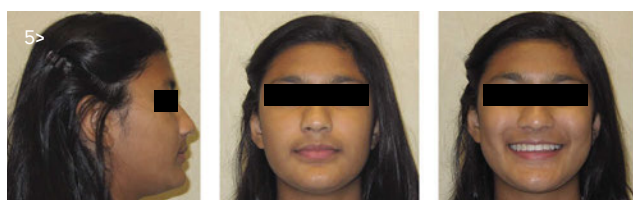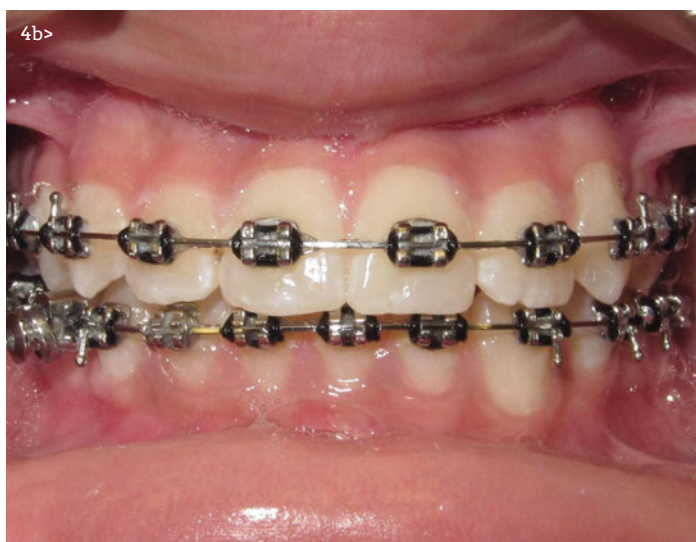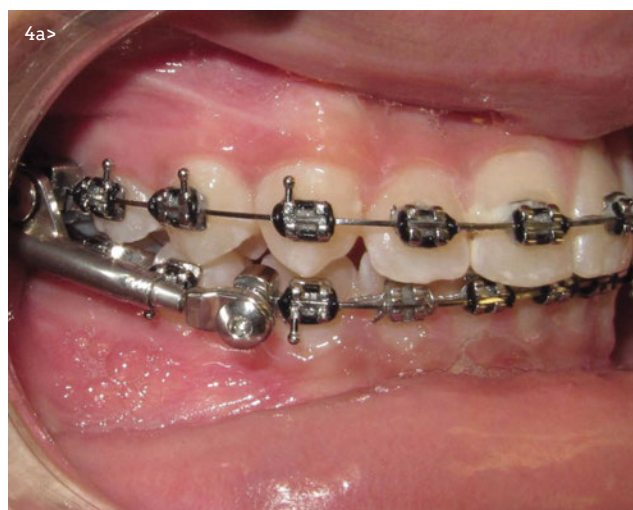2. Surgically expose the impacted transmigrated canine and attempt erupting it into proper position. This is, of course, the ideal scenario. However, other factors need to be considered such as risks to adjacent teeth during orthodontic traction, health of the periodontium, and length of time it will take for the required tooth movement. When measuring dental casts, the incisal tip of impacted canine would need to move 31mm for the desired result to be accomplished.
3. Remove the severely impacted tooth, leave the retained primary to hold bone levels and replace with a dental implant or fixed partial denture in the future.
4. Remove the severely impacted tooth as well as the first bicuspid in each of the other three quadrants for symmetry. This could provide a satisfactory dental result but this patient already has retroclined maxillary and mandibular anterior teeth and a nonextraction profile. It was my opinion that this would not lead to the best aesthetics in my hands.
5. Remove the severely impacted tooth and retained primary canine. Substitute for the missing canine with the first premolar.

After the five treatment options were presented, the decision was made to remove the transmigrated canine and to substitute for the loss of the canines with lower first premolars. It was perceived as the least invasive option and most cost-effective way forward. There would be no future restorations to maintain and no waiting period for a dental implant.

With a plan for substitution, after removing the impacted canine and retained primary this case can now be seen as a straight forward Class II subdivision case. The PowerScope Class II Corrector (Fig. 3) was planned to provide the force to the lower anterior for protracting the right premolars and molars into the substituted position. This is a wire to wire attached Class II corrector. When fully activated, it will consistently provide 260g of force for the protraction of the right buccal segment. The PowerScope has several advantages over Class II elastics for this situation. The compressed NiTi spring will provide a predominantly horizontal and only slightly intrusive push-type force mesial to the maxillary molar and distal to the lower canine position.

continued on page 28





Whereas, the pull-type force from Class II elastics are both extrusive and horizontal in their force vectors. Since there are no extrusive forces applied to the maxillary anterior teeth as with Class II elastics, the PowerScope can be used unilaterally without fear of canting the maxillary anterior occlusal plane in the aesthetic zone.

Other pleasing attributes of the PowerScope Class II:

- Compliance free
- One-size-fits-all chairside Class II solution
- Quick and easy wire-to-wire installation
- No headgear tube or special band assemblies required
- Can be used with banded or bonded molar tube
- Low profile for more aesthetic facial appearance
- Smooth, rounded design for better patient comfort
- Ball and socket joint for maximum lateral movement
- Telescoping mechanism that will not disengage during treatment

The only requirements to use the appliance are rectangular stainless steel archwires of 0.025" in the horizontal dimension. This will provide a precise fit for the direct-to-wire attachments and restrict the appliance from making unwanted movements and irritating the soft tissues. After working into a 16x25 SS wire, the Class II Corrector was placed unilaterally on the right side (Fig. 4). It's worth mentioning that by design the PowerScope is not intended to physically reposition the mandible anteriorly. Rather, the internal spring does the work while the patient functions in a maximum intercuspation position. Because of this, a significant midline discrepancy and a right side Class II buccal segment can still be observed clinically after appliance placement. The Class II Corrector was in place for five months and all appliances were removed after 26 months of fixed treatment (Fig. 5). It's apparent that good interdigitation and midline correction were achieved along with pleasing smile aesthetics. The stability of the correction two years into retention is notable (Fig. 6).

continued on page 30

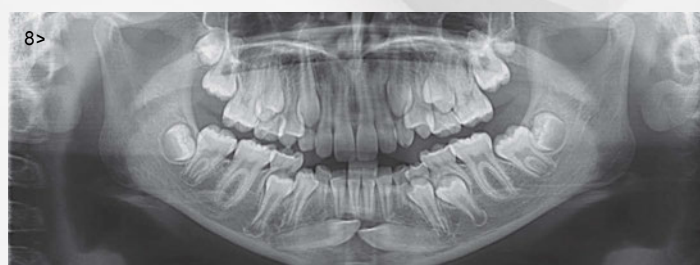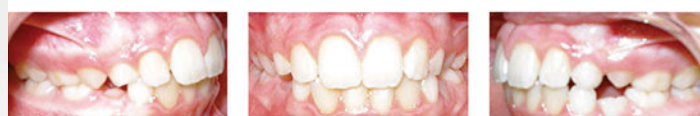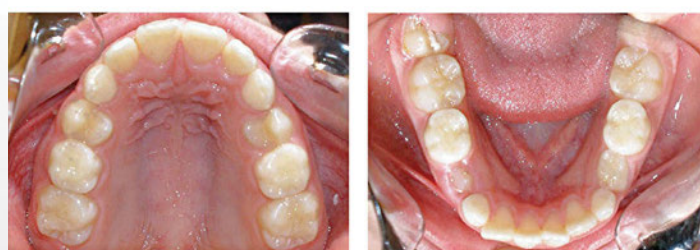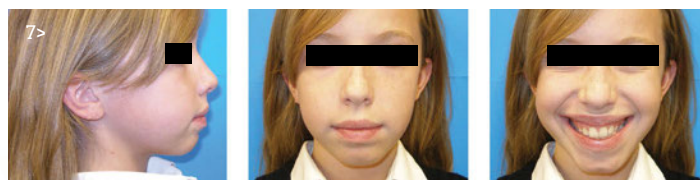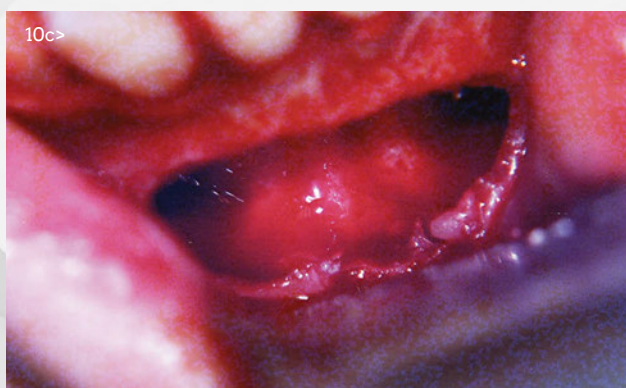
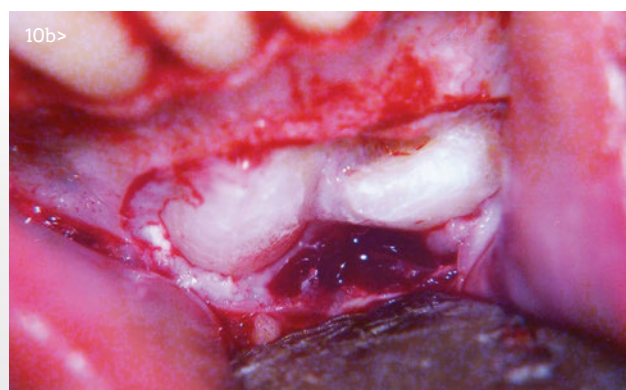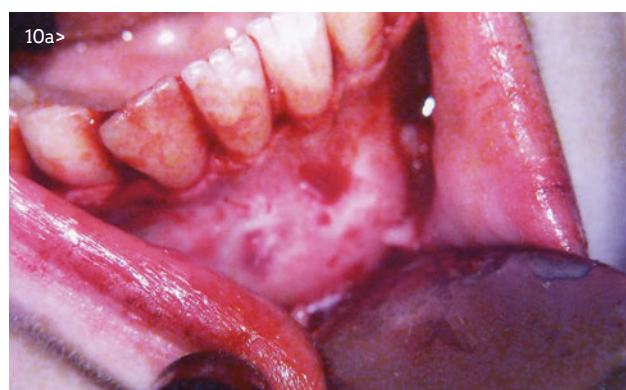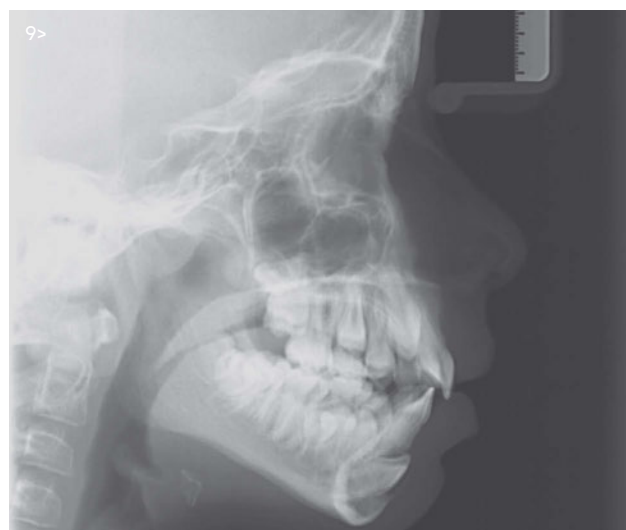Case study #2

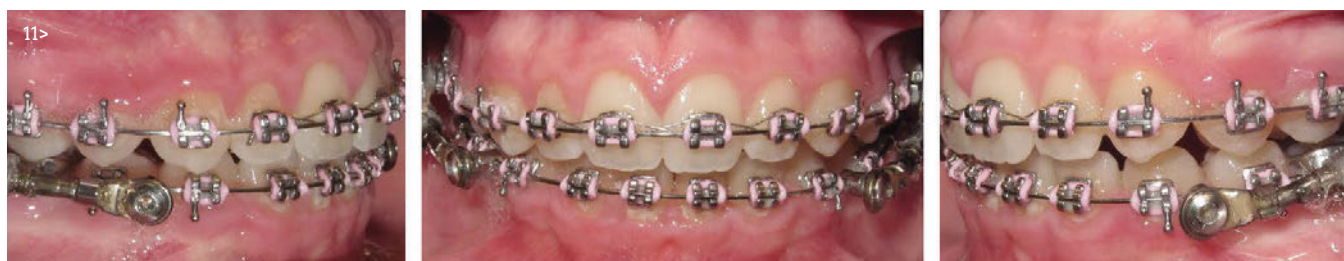This 11-year-old female presented to my office with a chief complaint of “dentist suggested it was time to see an orthodontist” (Fig. 7). Her health history was unremarkable. Analysis of the case shows an Angle Class II subdivision left malocclusion. Mandibular deviation to the patient’s left is apparent with lips at rest along with a pleasing soft tissue profile. The panoramic radiograph reveals bilateral horizontally impacted mandibular canine teeth (Fig. 8).

Although the patient’s profile is pleasing from viewing in the lateral direction, cephalometrics reveal a retrognathic mandible (Fig 9). The general theme of dentistry and also orthodontics is to save teeth if at all possible. However, oftentimes with cases involving transmigration the risks to adjacent teeth of the periodontium while attempting non-extraction treatments can outweigh the benefits. If having one transmigrated tooth is considered a phenomenon, I can’t begin to describe how unique someone must be to have both mandibular canines transmigrate. This is so rare that according to an article in *Dentomaxillofacial Radiology*, only 18 cases of bilateral transmigration had been reported in just 12 articles as of 2002.⁸

Again, multiple treatment plans were presented and the option to avoid any type of future prosthetic treatment was chosen. (Figs. 10a-c document the surgical process and the conservative nature toward the periodontium and adjacent teeth that can be accomplished while removing the transmigrated teeth.)

continued on page 32

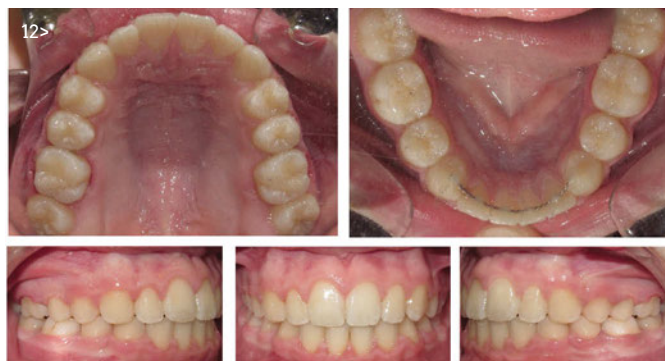



After tooth removal, appropriate hard tissue grafting was performed to fill the defect. After proper levelling and aligning, 17x25 SS archwires were placed and the PowerScope appliance was installed to protract the mandibular buccal segments against the entire maxillary dentition (Fig. 11). After 30 months total, the patient's treatment was completed (Fig. 12).

Discussion

These two cases represent not only the Class II corrective capabilities of the PowerScope appliance but the potential of spring-loaded Class II correctors in general for cases with mandibular tooth agenesis. By utilizing a horizontal force vector, the PowerScope has shown to be a terrific unilateral Class II correction option. The potential to close mandibular spaces in the cases of extraction and agenesis appears to be most beneficial. A dentition free from restoration can have major benefits aesthetically, functionally and monetarily. According to the American Dental Association 2011 Survey of Dental Fees⁹, the average fee by a general dentist for surgical placement of an endosteal implant body was \$1,741. The average general practitioner fee for fabrication and placement of a custom abutment and implant-supported PMF crown were \$760 and \$1,316 respectively. That comes to a grand total of \$3,818 per tooth. Keep in mind that these numbers



don't take into account additional charges for bone grafting, the higher average fees from specialists, or the adjusted costs for when our patients today are ready for the procedures in the future.

Conclusion

Spring-loaded Class II correctors can be utilized for more than simply what their name gives them credit. This article describes how a Class II correction appliance can double as a tooth moving engine for substitution in Class I patients. In 2011 terms, the few hundred dollars spent for the Class II appliance has saved the expense of thousands in implants and these patients are free from a lifetime of maintenance from restorations. ■

References

1. Bishara, S. (1992). Impacted maxillary canines: A review. *Am J Orthod Dentofac Orthop*, 101, 159-71.
2. Yavuz MS, A. M. (2007). Impacted mandibular canines. *J Contemp Dent Pract*, 8(7), 78-85.
3. Joshi, M. (2001, Feb). Transmigrant mandibular canines: a record of 28 cases and a retrospective review of the literature. *Angle Orthod.*, 71(1), 12-22.
4. Ando S, A. K. (1964). Transmigration process of the impacted mandibular cuspid. *J Nihon Univ Sch Dent*, 6, 66-71.
5. Aktan AM, K. S. (2010, Oct). The incidence of canine transmigration and tooth impaction in a Turkish subpopulation. *Eur J Orthod.*, 32(5), 575-81.
6. Camilleri S, S. E. (2003). Transmigration of mandibular canines — a review of the literature and a report of five cases. *Angle Orthod.*, 73(6), 753-762.
7. Bishara SE, K. D. (1976). Management of impacted canines. *Am J Orthod*, 69, 371-87.
8. Mupparapu, M. (2002). Patterns of intra-osseous transmigration and ectopic eruption of mandibular canines: review of literature and report of nine additional cases. *Dentomaxillofac Radiol*, 31, 355-360.
9. American Dental Association, Survey Center, 2011 Survey of Dental Fees.

What has been your experience with spring-loaded Class II correctors? Comment after this article on Orthotown.com.

Author's Bio



Dr. Andy Hayes received his DDS, MSD and certificate in orthodontics from Indiana University. He is listed as "inventor" on multiple orthodontic patents and has worked in conjunction with American Orthodontics to develop PowerScope. Dr. Hayes is a clinical instructor in the St. Louis University Department of Orthodontics and has presented lectures pertaining to Class II correction on three continents. He serves on the Editorial Advisory Board of *Orthotown Magazine* and maintains an active private practice limited to orthodontics in St. Louis, Missouri.